

Case Study - Arthritis, Bowed Tendon

"Silk"

17 y/o fox trotter gelding

Nitro PRO

Veterinarian diagnosis: Severe arthritis, old bowed tendons (both front legs) L. front inflamed due to improper bandaging, very poor front end conformation, over at the knees, contracted tendons.

Brief history: "Silk" was brought in to San Diego Equine Sports Therapy in 1999, to help heal a bowed tendon in his L. front. Diagnostic ultrasound showed an old bow in the R. front, and severe tendon and ligament damage in the L. front. This injury was approx. 2 months old. The owner had been treating by bandaging with a "Sports Medicine boot" pulled as tightly as possible, "to make the leg look good". The initial injury according to the treating vet, had only involved the inferior check ligament. "Silk" had been on 1 1/2 gms. phenylbutazone 2x daily, and was on a daily walking routine to help heal the tendon correctly. The horse was unable to walk more than 5 strides w/out stumbling and nearly going down. His feet were shod with very long toes, extremely underslug heels, and weighted shoes. At the veterinarian's recommendation, the shoes were pulled, feet trimmed w/ a 4 point trim, with toes cut way back. The horse stopped stumbling immediately. "Silk" was treated with therapeutic ultrasound, electrical stim, laser therapy, poultices, massage, support bandages, and hand walking. His tendon was unresponsive to all therapies. The tendon was injected, and this also did not help. "Silk" was very arthritic, and according to his owner, completely normal for him to lie down until late morning, then take nearly 15 minutes to rise. First swinging his head for momentum, then sitting like a dog, and eventually trying to stand. Then he would have to "walk it out". His gait was very stilted until he could loosen his muscles. He also colicked frequently, sometimes as often as every two weeks. He was treated with massage, chiropractic, and acupuncture therapies administered by veterinarians. He was put on joint supplements, had an Adequan series, all to no avail. His owner needed a sound trail horse, and decided to get another horse.

"Silk" was given to the facility for back board due. Three different veterinarians felt there was nothing more that could be done to help this horse. He was still unable to rise without great difficulty, and his colic episodes were frequent. An enterolith was suspected. Upon new ownership, the phenylbutazone was stopped, as he had been on it for many months. He continued joint supplements, and Adequan, but they did not seem to help him. He was moved to a turnout area where he could move at will, and this helped a little.

"Silk" was finally put on Nitro PRO. The human formula "Hemoxide" had benefited the owner greatly with arthritis of the back, and wanted to try it on the horse. "Silk" was given 45cc powder two times daily for a month. Then backed down to one time per day. After 3 days on the Nitro PRO, "Silk" was able to rise almost like a normal horse, and did not have to "walk it out" to get the stiffness out of his body. After 30 days on Nitro PRO, The horse was consistently much more comfortable than he had been in months, and his colicking episodes had stopped. He became the pride and joy of the owner's 3 year old little girl. She rides him with only a halter and lead rope, and he happily lets her lead him all over the property. He has become a million dollar/ \$1 horse. "Silk" remained on maintenance doses of the Nitro PRO for 2 more months and was then weaned off of it. When he had appeared to be stiff and uncomfortable again, he was immediately put back on the Nitro PRO, with excellent results every time. He has had zero colic symptoms in the 3 years since he first began the Nitro PRO. Veterinarians suspect that he possibly had gastric ulcers that were causing his frequent pains. **Nitric Oxide has been proven to heal gastric ulcers. He and his owner Hannah just went into their first horseshow, leadline class, and won a blue ribbon.**

Case Study - Bowed Tendons

"Spring"
33 y/o 1/2 Arabian gelding

Injury PRO

Veterinarian diagnosis: Both front tendons bowed, severe muscle soreness, old horse over did it.

Brief history: March 2002, "Spring" at 33 years of age was found down in the pasture, and with great difficulty was forced to rise and walk approximately 75' into a barn stall. He showed no obvious signs of injury, his temperature was normal, perfusion was normal, gut sounds normal, and an elevated heart rate of about 60/min. His body was in spasms, mostly neck and shoulders and chest areas. His tendons on both front legs showed only mild heat and no tenderness. The treating veterinarian felt the tendons were not damaged, and needed no treatment except possibly support bandages. He felt the old horse had simply "over done it" and prescribed 2 gms. phenylbutazone 2x daily, and/or 10cc Banamine IV 2x daily, as needed for pain, for 30 days.

The horse's pain was not noticeably relieved with either the phenylbutazone or the Banamine, and both were consequently given, with only very temporary results. After medicating, "Spring" was able to rise and eat, but would only eat about 1/2 of his feed and would lie down again. His tendons became extremely inflamed within 24 hours of seeing the first veterinarian, and a second veterinarian was called who said they were both severely bowed. His tendons were treated with ice and poultices, and support bandages, changed two times daily, until the heat was gone. After the heat was gone, he was treated with just support bandages, and magnetic wraps for several hours per day, then liniment and bandages at night. He remained on the Bute and/or Banamine for 30 days. He was unwilling to stand and eat without the medication. He became very depressed, and spent most of the time lying down, and ate less and less. "Spring" was losing weight, and was very lethargic, when he did walk, it was very slow and for only a few steps, then he would stop again. He seemed to have given up on life. Prior to this injury, this horse had been very active, and had always seemed very healthy. He had the same owner since 1971.

After 30 days, the owner decided to take him off all the medication and put him on Injury PRO. "Spring" was given 60cc Injury PRO 2x daily. After 3 days, he was no longer lying down between feedings. His appetite increased dramatically. After approximately 7 days, he was hardly lying down at all, and was back to a normal appetite. He was treated for 30 days at 60cc 2x per day of the Injury PRO, then 60 cc 1x per day for 2 weeks, then 30cc 1x per day for another 4 weeks. He was initially stalled, then in a paddock with his own stall, but after 1 month on the Injury PRO, he was walking and acting normal again, and was put back with his friends in the pasture. He still received his own bucket of senior feed, and would not allow any other horse to push him away from his bucket. His coat blossomed more than it had in years. For the last 5 years he had looked like a Cushings horse, and had been tested yearly, but tests always came back negative. "Spring's" coat after being on the Injury PRO was a deeper bay, totally glossy, and had beautiful dapples in it. His owner couldn't believe it. "Spring" lived almost to his 34th birthday. He died Jan. 3, 2003.

CASE STUDY - Bute Toxicity & Protein Losing Enteropathy

"APRIL"
AQHA Filly
DOB 4/2/02

GastroPLUS PRO™ and Pulmon-EZ™

Abstract

A weanling AQHA filly suffered from protein-losing enteropathy due to Bute (phenylbutazone) toxicosis. She had been administered the Bute following an adverse reaction to her routine vaccinations. She was treated by several different veterinarians, and hospitalized two times. She underwent various different treatments including plasma transfusions, hetestarch transfusions, antibiotics (Naxcel, penicillin, and SMZ's), and pink bismuth. She suffered from chronic diarrhea, dehydration, anorexia, severe colic episodes, weight loss, high fevers and intermittent facial swelling. In addition to these she also suffered from chronic upper respiratory disease. After 5 months of illness, numerous vet bills, and various treatment regimens, a new veterinarian was introduced to the case. After numerous diagnostic tests, the diagnosis was protein-losing enteropathy. This filly began treatment with GastroPLUS PRO™ and Pulmon-EZ™. After 5 days treatment with GastroPLUS PRO™, this filly finally had a normal day and her progress continued from that point on. 5 weeks later, Pulmon-EZ™ was added to the treatment regime for the respiratory illness she had suffered from for months. Within 24 hours after beginning Pulmon-EZ™, her cough and snotty nose cleared up. She continued treatment with Pulmon-EZ™ for approximately 10 days. Treatment with a total of 4 bottles of GastroPLUS PRO™ were used intermittently over a period of 7 months and completed by September 24, 2003. As of March 14, 2004, she still healthy and has begun ground training.

Case Study: GastroPLUS PRO™ and Pulmon-EZ™

On September 5, 2002, April, a weanling 5-month-old AQHA show filly was vaccinated with 4 ways, flu/rhino, rabies, and West Nile Virus (WNV). The filly had been vaccinated at birth, 3, and 4 months of age for all of the above except WNV, without any adverse reactions. This was her first and only WNV vaccine. The day following the vaccinations the filly's head, vaccination area, chest and legs were significantly swollen. She had developed edema from her chest to along her ventral line. She was unable to walk without pain, was off her feed, stopped drinking, and had diarrhea. The treating veterinarian recommended 1 gm Bute 2x per day. On September 7, 2002, while administering the Bute via paste form, the ring slipped and an overdose of 6-7 grams was administered. The filly developed diarrhea and stopped eating and drinking. Pedialyte, salt water and Red Cell were given by the owner to avoid dehydration and help stimulate her. On September 9, 2002, the veterinarian examined the filly and in his opinion she was not dehydrated, but prescribed probios paste to help stop the diarrhea. GastroGuard was also prescribed but declined due to the high cost.

September 12, 2002, April was examined by another veterinarian who diagnosed "Bute toxicity" and referred her to an equine hospital where she was placed in ICU. Blood work determined that she was losing proteins rapidly, they were at 3.4. (Normal is 5.2-7.9 g/dL). The WBC was also low. A small ulceration was detected in the intestine but with no signs of perforation. She was treated with IV fluids, 2-3 liters plasma and also hetestarch transfusions, antibiotic therapy with Naxcel, and pink bismuth for the diarrhea. Hetestarch is a commonly used colloid. It is produced by chemical modification of the starch amylopectin, through hydrolysis and hydroxyethyl substitution, and is a modified branched chain glucose polymer. April was given only a 20% chance of survival. Between September 15 and September 22, 2002 April's condition was up and down. The edema continued on her legs, chest and neck areas. Euthanasia was mentioned at one point. By September 23, 2002 she was eating and drinking well on her own. Protein was up to 4.0, and sodium up to 137 (normal is 136-142 mEq/L). The following day September 24, 2002, the filly had begun to develop pneumonia. Her protein dropped to 3.6 and her WBC also

dropped. More plasma and hetastarch transfusions were administered and antibiotics were increased. By September 27, 2002, her blood work was normal and the following day she was released to go home.

By 6 P.M. on April's first day home, she became uncomfortable, bloated and gassy. Owner administered Banamine and whisky and hand walking was done with some improvement, but by 5 A.M. she began thrashing and threw herself down, and was taken back to the ICU. IV's were again administered, and numerous diagnostic tests were run. Her temperature was 104 F and her proteins and WBC were way down. Surgery was contemplated, but due to her extreme weakness was decided against. If she continued to worsen, euthanasia was again to be considered. She received another plasma transfusion, continued to improve and was discharged on October 5, 2002.

On October 22, 2002, April began swelling around her jowls, cheeks and chin. Hot packs would reduce the swelling and the veterinarian suspected that her teeth were bothering her and placed her on SMZ antibiotics. She developed a fever of 102 F, her diarrhea resumed, and she became gassy again. She had tremors and chills, was blanketed with 2 blankets and put under heat lamps. Banamine and whisky were again administered. Her swelling and fever continued and the treating veterinarian thought she may have a tooth abscess and wanted her to continue antibiotics. Another veterinarian felt she was too young for teething problems and felt she had developed the flu, he recommended penicillin. The swelling, low-grade fevers, diarrhea and gassy spells were intermittent through the month of November. By December, the fevers had subsided, but the chronic swelling of her face, cheeks, throat and jowls, and the soft stool continued through December and into the middle of January 2003.

January 9, 2003, when April tried to exercise herself, she developed a cough and snotty nose.

January 19, 2003, the filly's snotty nose worsened and she began to have the chills again. A new veterinarian was called in. He suggested the following tests: Glucose absorption test to test for juvenile diabetes; malabsorption tests; anti-nuclear work up; CBC, and an intestinal biopsy (not feasible due to cost). He also wanted to test proteins and Albumin levels. The above tests were performed and the diagnosis was Protein Losing Enteropathy. He recommended ulcer medication, and in 4-6 months re-run CBC and ANA tests.

On January 26, 2003, April's owner ordered GastroPLUS PRO™ for the treatment of gastric ulcers.

On February 4, 2003, her snotty nose was still present and she began treatment with Naxcel 12cc 2x per day, to aggressively combat the respiratory infection.

February 5, 2003, April began treatment with GastroPLUS PRO™, at 45cc oral 2x per day. That evening before the initial dosing, the filly's symptoms were still the same, snotty nose and chin swollen. The following morning no swelling was present, and she was dosed again. But by evening her jowl and chin were swollen again. After dosing with GastroPLUS PRO™ in the evening, the swelling was down within 2 hours.

February 6, 2003, her swelling episodes were reduced and after dosing with GastroPLUS PRO™ the swelling would be eliminated. On February 8, 2003, AM, her head was completely swollen. After dosing with GastroPLUS PRO™ the swelling was down within an hour. That evening she was found down, suffering from chills and tremors, swelling was back and she was not eating. Again she was dosed with GastroPLUS PRO™ and by 9 P.M. she no longer had the chills, and her swelling was gone. She had some swelling around her chin and jowls and again after dosing with GastroPLUS PRO™ the swelling was gone.

February 9, 2003, was the last day of treatment with the antibiotic Naxcel.

February 10, 2003, her fifth day on GastroPLUS PRO™, was her first completely normal day. The following day she finally had normal stool for the first time since Sept. 6, 2002.

While April was responding favorably to the GastroPLUS PRO™, and showing signs of recovering, she still had a way to go. When the dosages of the GastroPLUS PRO™ were reduced from 45cc powder to 30cc powder on February 13, 2003, she began to show some slight swelling again, and also began a golf ball size lump in her throat. Her respiratory illness continued to be a problem in spite of the Naxcel she had received for 6 days. Even though she still had the snotty nose, by February 15, 2003, she was very bright and beginning to show an attitude. April started getting some exercise and turn out time. April was improving very well, and had more normal days than not, with her energy level increasing. Swelling was infrequent now, but the snotty nose would keep reappearing.

By February 27, 2003 she appeared normal, attitude was good, swelling diminished, stools normal, but she had started to develop a cough. It worsened and her snotty nose continued.

On March 15, 2003, Pulmon-EZ™, another nitric oxide delivering product was added to her treatment regime. Pulmon-EZ™ uses nitric oxide precursors to support lung function and to help combat chronic respiratory disease. April had not been able to shake this respiratory illness that began on January 9, 2003, even though she had been on Naxcel and penicillin several times over the previous months.

April began **Pulmon-EZ™ in addition to GastroPLUS PRO™ on March 15, 2003, and her respiratory illness, snotty nose and chronic coughing ceased by the next day.** April remained on Pulmon-EZ™ for less than 2 weeks, as **her symptoms were relieved immediately.** She remained on GastroPLUS PRO™ and was gradually weaned off of that product. First by lowering the dosages, then decreasing the frequency of doses. By May 18, 2003, she was dosed with GastroPLUS PRO™ every other day and then only twice a week. She has not had any GastroPLUS PRO™ since September 24, 2003. Every so often she will have a little swelling in her jowls, or some softer stool. Overall April is now in very good health. With everything the owner has been through she found that in addition to successfully treating her internally with GastroPLUS PRO™ and Pulmon-EZ™, that her feeding has also been a factor in April's condition. Coarse hay is not well tolerated, so only fine stem hay is fed to April. April and all the others at this facility owned by Vicki Spina- Maraugh are very well cared for, and follow a strict de-worming and vaccination program.

Protein losing enteropathy is a disease affecting the gastro intestinal system resulting in protein loss when the epithelial cell barrier is lost due to mucosal ulceration, or when interstitial edema disrupts the tight junctions between epithelial cells. Protein-losing enteropathy has most commonly been associated with mucosal absorptive defects such as granulomatous enteritis, eosinophilic gastroenteritis, gastrointestinal neoplasia (lymphosarcoma, and squamous cell carcinoma), intestinal parasitism, acute salmonellosis, congestive heart failure and NSAID toxicity. April's Protein-losing enteropathy is thought to have been caused from NSAID toxicity, the Bute overdose she received when the plastic ring slipped on the paste Bute she had been administered. Bute was prescribed to try and relieve the pain and swelling caused by the reaction to her vaccines. According to research, severe intestinal protein loss from mucosal ulceration resulting from NSAID toxicity is caused from high doses of phenylbutazone (Bute) or other NSAIDs given over a period of several days. Experimentally, hypoproteinemia has developed in horses even when a standard dosage of NSAIDs has been administered. The implication is that stress and dehydration increases the susceptibility of the horse to the adverse affects of NSAIDs. April was already experiencing diarrhea, and was quite possibly dehydrated before the Bute was administered.

Experimentally induced Bute toxicosis in ponies produces ulcerations in the mucosa of the tongue, gingiva, hard palate, stomach, small intestine and the colon. Gastric ulceration induced by NSAIDs involves increased gastric mucosal permeability to hydrogen ions, inhibition of mucus synthesis, and decreased gastric mucosal blood flow. **There is growing evidence in humans that NSAID toxicity (example: ibuprofen) increases permeability of the small and large intestinal mucosa by damaging the intercellular junctions.** Bacterial invasion of the submucosa after damage to the mucosal barrier appears to be important in the pathogenesis of the ulcerative lesions.

Phenylbutazone (Bute) toxicity has been thought to be a cause of protein-losing enteropathy attributable to extensive ulceration of the right dorsal colon. Gross examination has revealed severe diffuse ulceration

and congestion of the tunica muscularis. Fibrinonecrotic debris partially covers the ulcerated mucosa. Microscopic examination reveals a mixed population of inflammatory cells and fibroblast proliferation. It is postulated (a set of criteria for judging whether a given bacterium is the cause of a given disease) that small ulcers form initially and are then invaded by colonic bacteria. Mucosal regeneration is impaired and a chronic active disease results.

Clinical signs usually associated with protein-losing enteropathy include: lethargy, exercise intolerance, weight loss, diarrhea, intermittent colic and dependent edema. The edema is secondary to low plasma oncotic pressure caused by hypoalbuminemia. Anorexia, depression and weight loss are the most common clinical signs when gastric squamous cell carcinoma is present. Acute colic and clinical signs of endotoxemia sometimes occurs in protein-losing enteropathy caused by NSAID toxicity or severe intestinal parasitism.

Laboratory findings: Hypoalbuminemia with decreased, increased or normal plasma globulin concentrations characterizes the plasma protein changes in protein-losing enteropathy. Because hyperglobulinemia occurs in many different gastrointestinal diseases, total plasma protein concentrations are often normal. Quantitation of protein fractions is an important laboratory evaluation when protein-losing enteropathy is suspected. With horses suffering from granulomatous enteritis, early intestinal protein loss involves relatively greater quantities of albumin than globulins, whereas all protein fractions may be lost in the later stages of disease.

Recommended treatments for protein-losing enteropathy involve managing the primary disease and/or treatment of hypoproteinemia. Plasma transfusions are necessary when total protein concentration decreases below 4g/dL. It must be realized that continued protein losses tend to decrease the efficacy of the plasma transfusion. NSAID therapy should be discontinued if hypoproteinemia or signs of gastrointestinal disease are noted. For NSAID toxicity, broad-spectrum antimicrobial drugs can help. Cimetidine (Tagamet) and other histaminergic receptor antagonists allow the body's own healing process of the gastric ulcers, but do not treat protein-losing enteropathy. It is advisable for horses receiving Cimetidine to be monitored for kidney and liver functions. In rare cases in humans receiving this drug, decreased white blood cell or platelet counts were also reported. Sucralfate (Carafate) will also help promote the body's own healing process of the gastric ulcers, and may increase production of prostaglandin E. Sucralfate is poorly absorbed, and also binds to and partially prevents absorption of some drugs like ranitidine and cimetidine, some oral antibiotics, phenytoin, and digoxin. Surgical resection of the affected portion of the right dorsal colon for ulcerative colitis has been recommended in some cases. The prognosis for horses with severe NSAID toxicity and right dorsal ulcerative colitis is guarded whether or not surgery is performed. Dietary management consisting of feeding pellets and restricting roughage may benefit some horses suffering from protein-losing enteropathy. Treatment of granulomatous enteritis with corticosteroids, salicylazosulfapyridine, azathioprine, and isoniazid has been attempted without success, and the prognosis for recovery is poor.

GastroPLUS PRO™ was not only created to help increase necessary mucus to line and coat the stomach and intestinal linings to allow the body's own healing process. More importantly GastroPLUS PRO™ helps provide crucial nitric oxide formation. Studies have shown that insufficient amounts of nitric oxide will allow the intestinal walls to become damaged, and to possibly perforate. These same studies have also shown that by increasing nitric oxide that the intestinal walls not only heal, but also become resistant to damage. **One study done at the University of Calgary in 1995 states that with sufficient nitric oxide, they were unable to damage the intestine. This same study also addressed the question of possibly dosing with too much nitric oxide, and would it be harmful? This study concluded that nitric oxide is necessary, and excessive amounts of nitric oxide are not considered harmful, but instead are beneficial.** The researcher who headed these studies was Paul Kubes Ph.D. Dr. Kubes was awarded the 1995 Gastroenterology Young Investigator Award from the American Gastroenterology Association for this CCFC funded work. The University of Calgary and Assistant Professor Paul Kubes PhD also received new funding from the CCFC to continue this work for 1996-1999 for the role of iNOS in models of Inflammatory Bowel Disease.

Testimonial from Vicki Spina-Maraugha, owner of April:

In August 2002, our filly April was given the West Nile Virus shot to comply with our 4-H State show rules. Within hours of receiving the shot, she began to swell throughout her head. By the next morning, her entire head was swollen, along with her legs and the underline of her belly, plus a large lump in her chest. Upon the next call to our vet, she was given a regimen of Bute, which happened to be a toxic dose for a filly of this age (6 months). April was rushed to the nearest equine ICU and given a 20/80 shot of survival, not in her favor. After tons of medications, tests and an extraordinary amount of money were expended, the vet suggested putting her down or placing her on Gastro Guard for her ulcerated intestines, which happened to be \$975 per month. I couldn't see spending the money that I didn't have on a 20/80 shot, nor did I want to put her down, so she was brought home. I used home remedies such as Pepto Bismol to coat her stomach while I searched the Internet for solutions. I then found the web site for GastroPLUS PRO, and began to email my story and shortcomings to its owner. At that time, he suggested his product, GastroPLUS PRO™, which was more cost efficient and offered money back guarantee, so I couldn't really lose anything. After 2 weeks on this product, April began to eat a whole portion of her feed and finish it, along with improving in brightness and had limited swelling. I used this product for approximately 7 months and now April is living a healthy, normal life, with very few problems. With a corrected high fiber diet and an occasional dose of GastroPLUS PRO™ to keep her levels up, she is now being started into training.

March 22, 2004

Vicki Spina-Maraugha
Scenic View Acres
Adah, PA

References: GastroPLUS PRO™ and Pulmon-EZ™

Vicki Spina-Maraugha "Aprils Daily Diary"

Susan Clark Eades, DVM, PhD, Dipl ACVIM "Equine Medicine and Surgery" fifth edition "Diseases Affecting Plasma Proteins"

William P. Hay, DVM, Dipl ACVS and P.O. Eric Mueller, DVM, PhD, Dipl ACVS and Janice E. Sojka, VMD, MS, Dipl ACVIM "Equine Medicine and Surgery" fifth edition "Diseases of the Small Intestine"

Paul Kubes PhD CCFC Journal-fall 1996- Epithelial Permeability in the Healthy and Inflamed Intestine

Eleanor M. Kellon, VMD "Equine Drugs and Vaccines"

K. Gary Magdesian, DVM, Dipl ACVIM and ACVECC "Colloid Replacement in the ICU" "Clinical Techniques in Equine Practice", Vol 2 (June) 2003 pp 130-137

Case Study - Laminitis

"Spring"
33 y/o gelding

Nitro PRO™

Veterinarian diagnosis: 33 y/o horse with suspected cancer of the stomach/abdomen. Also suspected, possibly EIA, or an immune deficiency disorder.

Brief history: 12/18/02 Spring was lethargic, had a low grade fever, and diarrhea. Veterinarian suggested caretaker pull blood for a panel, and begin SMZ's, and Bute. (It was at night, and he was unable to respond to the horse.) Blood was run the following day, and the vet called and said he needed to see the horse ASAP. Upon examining the horse, he felt strongly "Spring" was suffering from stomach/abdominal cancer, and suggested euthanasia. The owner wanted to try and see if it was possible anything else could be his problem. More blood was drawn, along with an order for a Coggins test to rule out EIA. Coggins test came back negative, but blood work showed a remote possibility of an immune deficiency disorder. His owner wanted to try and save him. 12/22/02 "Spring" began treatment with 50cc dexamethasone 2mg/ml IV, and Uniprim powder, and banamine 4.5cc 2x daily. Platelet count was 12k, and Platelet rich plasma was ordered. "Spring" received the antibiotics and 25cc dexamethasone daily, for 13 days. He received the platelet rich plasma transfusion, and blood was drawn every few days for a new panel. The vet felt strongly that he had cancer, but the owner was still wanting to try. The vet expressed his concerns over the fact that while the examethasone was a necessary part of treatment, this high of a dose, daily, especially with "Spring" being so ill, would very possibly cause him to suffer a severe case of laminitis, if he did survive. With this worry in mind, **Banamine was discontinued, and he began high doses of Nitro PRO, 60cc powder two times per day, three times per day whenever possible.** "Spring" did show improvement in health, and blood work, platelets did increase even better than hoped for. The treating veterinarian was very surprised every time he examined "Spring" that he had zero digital pulses, or any other signs of laminitis. The credit was given to the Nitro PRO, for possibly preventing the onset of laminitis. The treating veterinarian was correct with his initial diagnoses; "Spring" succumbed to cancer on Jan 3, 2003.

Even though "Spring" did not survive his cancer, his case showed definite possibilities for the use of Nitro PRO in preventing laminitis for other horses having to undergo severe stress of illness, and/or having to receive steroids, or put in situations that may cause on onset of deadly laminitis.

Case Study - Chronic Laminitis

"El Patron"
10 year old Black
1/2 Paso, 1/2 AQHA gelding
15.2hh, 1050 lbs

Injury PRO™ and Nitro PRO™

"El Patron", was purchased as a 2 1/2 year old by his present owner. His owner describes him as a little horse, about 15.2hh, with a big appetite. His weight is estimated at 1,050 lbs. "El Patron" was very slow to mature, and didn't reach maturity until, he was about 6 years old. He had a tendency to be tender footed. He was kept at a facility in an in and out situation. He was fed hay and grain 2x per day, and was kept in the stall free to go into the corral 99% of the time. He did not have any access to green grass. But were

showing signs of tender footedness and also had shelly feet that the farrier had a difficult time keeping shoes on. It was suspected that the horse was suffering from mild bouts of laminitis.

When the horse was 5-6 years old, he was moved to another facility where he had access to grass and he suffered an acute laminitic episode. Radiographs revealed approximately 3 degrees rotation in each front foot. "El Patron" was taken off grass, and heart bar shoes were put on. He also underwent a procedure that used a router to drill into the hoof wall and lamina to allow drainage. He seemed to respond and get better, but was not completely sound. After 6-8 months the owner began riding him lightly again, and with work, his lameness would worsen. He continued to chronically be worse and better, but never fully recovered.

December 2001 the owner got involved in the Strausser method of treating laminitic horses. The farrier began working on the horse, keeping him barefoot, taking his heels off, and keeping the horses feet moist by having him stand in the water overflow from the water tank. He had forced exercise to increase the blood flow to the feet. It took approximately 3 months of weekly trims, and the horse appeared to get better. After about 1 1/2 years the horse became more rideable, but he was still sore and his problems were not solved.

The horse was administered Bute (phenylbutazone) on and off over the last 4-5 years when he was painful, with it providing some relief.

"El Patron" was also put on thyroid medication for an under active thyroid. Cushing's disease was not suspected, nor tested for. He remained on the thyroid powder for several years.

He was regularly taking a biotin supplement called "Nu Foot".

It appeared that "El Patrons'" worst times were in the fall. The owner feels it was because he kept him off of the spring grass.

On November 9, 2003 "El Patron" suffered his worst attack of laminitis. He was out on lush pasture, and his owner found him standing in the pasture, weight back on his haunches and holding his left foot up. He was hardly able to make it into his deeply bedded stall. The owner said he initially thought the horse had sustained a fracture of that leg. "El Patron" had a corral outside of his stall and was not closed in. He was found outside lying in the mud by his water trough. Getting him back into the stall was very difficult for the horse, he would hop, weight on haunches and try and not bear any weight on his front feet, barely touching with his toes only. His owner said he would sweat profusely with nostrils flaring, and blowing hard just to take a few steps. He was still eating, but his appetite was decreased due to the pain.

"El Patrons'" owner saw an ad for Nitro PRO™, a formula for aiding in treatment of laminitic horses.

November 15, 2003, Nitro PRO™ a Nitric Oxide delivering product, was started at 1 double dose per day. (A single dose is 3cc powder per 100 lbs body weight; a double dose is 6cc per 100 lbs.) After 4 days on the product, the horse was able to stand comfortably in the stall.

After the first bottle, the owner decided to change to another Nitric Oxide delivering product called Injury PRO™. This decision was made because he was still giving the "Nu Foot" biotin supplement, and Injury PRO™ formula also has biotin in it for aiding in the repair of the hoof.

December 12, 2003, The horse had abscesses drain from the coronary band on each foot. Abscesses can occur up to 3 months after the initial insult to the lamina. They occur in areas of dead or dying lamina or solar corium, between the pedal bone and the hoof wall.

"El Patron" continued responding well to the Nitric Oxide delivering product Injury PRO™, and by January 15, 2004, he was moving completely sound. He was never confined to his stall but was allowed in and out as he pleased, into a paddock with the grass mowed short.

His dosages remained at 1 double dose per day until the end of January, and then were reduced to a single dose 3x per week. He is still on a single dose 3x per week. He appears to be the most comfortable and sound he has ever been in the last 4-5 years.

Radiographs were taken in March of 2004 and show 14 degrees rotation in both front feet. With encouragement, the owner is going to consider a program to gradually de-rotate him now that he is comfortable and moving well. "El Patron" will stay on Nitro PRO™ at a single dose 3x per week for the rest of his life.

Nitro PRO™ and Injury PRO™ are both uniquely formulated using the precursors that increase Nitric Oxide production. Nitric Oxide is a gas molecule that causes vasodilation of the vessels, greatly increases circulation, and is an excellent anti inflammatory and pain reliever. Nitric Oxide is also crucial in establishing the body's own healing process and increasing cellular production to quickly heal the damaged lamina. Giving these products to the laminitic horse allows the horse to stay in a deeply bedded stall, without having to painfully walk to increase the blood flow to the tissues. Unfortunately, walking causes tearing of the already compromised lamina, thus increasing the chances of the coffin/pedal bone rotating or even sinking. We encourage the veterinarian to be aggressively involved in the horses care. We recommend addressing the issues that caused the onset, and diagnostics to determine the extent of damage that has occurred. We also recommend the veterinarian and farrier work aggressively together to help support and stabilize the horses damaged foot. With aggressive treatment and allowing the Nitric Oxide delivering products to increase the circulation to the damaged lamina, the inflammation that causes damage and death to the lamina and pedal bone, will be reduced and the the body's own healing process speeded up. This greatly reduces the horse's pain, and increases the horses' chances of a complete recovery. Laminitis is a devastating disease, and one that should be treated as an emergency. Proper aggressive treatment at the onset is the best-case scenario for every laminitic case.

A testimonial from "El Patrons" owner Mr. Larry O'Bryan of Texas: "I believe these products saved my horses life, and he will continue on maintenance doses for the rest of his life."

Recommended reading:

UNDERSTANDING LAMINITIS by Ric Redden DVM

EXPLAINING LAMINITIS and its PREVENTION by Robert A. Eustace BVSc Cert. E.O. Cert. E.P. MRCVS

ALL ABOUT LAMINITIS by Karen Coumbe MRCVS

(All of these titles are available through amazon.com)

Case Study - Recurring Laminitis

Horse's name: Touché
21 year old mare, DOB 4-21-79
½ Arabian, ½ Quarter Horse
14.2 HH
1050 lbs. approximately



Same owner since 1980

Primary use: as a back yard pleasure horse and lesson horse

First episode of laminitis: attending veterinarian Kevin May, DVM

Second episode of laminitis: attending veterinarian Kim Sergeant, DVM

Nitro PRO

In the fall of 1998 Touché had colic surgery and an ovariectomy.

Two days post-surgery she developed salmonella and 6 days post-surgical developed a totally occluded thrombosed jugular vein. Touché was released to go home eight days later. Approximately 3 months post-surgery Touché developed acute laminitis in both fore feet with grade-4 symptoms. Touché was unable to walk without forcing herself. Both fore feet were hot to the touch with strong digital pulses medial and lateral. Her hind feet were negative.

The treating veterinarian, Kevin May, DVM, recommended Bute, Acepromazine twice a day, and Banamine as needed for pain. Touché was fitted with Ric Redden Ultimate Shoes on her fore feet, which were both causing her very noticeable discomfort. A laser (850 nm Thor DD) was used daily to stimulate all acupuncture points surrounding the coronary band. The Thor Cluster Probe with a 69 diode 950 nm 15 mw output was applied on both sides of the fetlock and on the heel and front of the pasterns. Laser treatment was followed by electrical stimulation administered using the Theroquine Electrical stimulator for 45 minutes on each pastern daily.

Laser and electrical stimulation was administered by the San Diego Equine Therapy Center. Treatment lasted for 30 days and resulted in an absence of any detectable pulses within 60 minutes of each treatment. However, pulsing would return the day following each treatment.

The Ric Redden Ultimate Shoes were re-banded in place daily. After approximately 30 days, as the pulses decreased, therapy was reduced to every other day, then every third day as pulsing ceased. Pulses were checked a minimum of four times daily for a period of approximately three months total. If pulsing was detected, laser treatment and electrical stimulation treatment was administered.

After approximately six weeks, the Ric Redden Ultimate Shoes were replaced with reverse shoes with two wedge pads. After pulses stopped completely the pads were reduced to one wedge and six weeks later were changed to a reverse shoe. Radiographs were taken two weeks post-onset and again at eight weeks post-onset by Gary Amaral, DVM. Radiographs showed zero rotation in either foot.

Touché's diet at onset was changed from Alfalfa Bermuda mix to Bermuda Hay only. The mare initially was in such pain and so depressed that she would not eat. Alfalfa was slowly introduced back into the diet as she slowly progressed. Touché was considered to be at a good weight and in good condition therefore weight loss was not considered. She was housed in a deeply bedded barn stall for comfort.

While Touches' laminitis appeared to be resolved, she never became fully sound again. She was able to do very little exercise, hand walk, hot walking, or turn around in very soft paddocks. While radiographs were negative of any abnormalities, she continued to show discomfort, especially on hard and even surfaces.

Second Episode Of Laminitis

On March 1, 2000 Touché's head begin to swell around her right eye and cheek. This edema would increase and decrease each day and did not appear to worsen. Touché's veterinarian, Kim Sergeant, DVM felt that a thrombosed right jugular vein was the cause of the swelling. In April 2000 Touché's head began to swell on the right side to such an extent that this ½ Arabian mare had to wear a draft size halter. At approximately the same time, Touché's farrier had recommended putting the mare's shoes on normally.

Within a day Touché then suffered another bout of laminitis. She was a grade-3, reluctant to move, with bounding digital pulses medial and lateral on both fore feet, which were very warm to the touch. It was

considered that her shoes were causing her pain. Therefore, her shoes were gently pulled, toes squared off and Ric Redden Ultimate Shoes taped back in place. However, this time there was no noticeable pain relief.

Bute was given twice daily and Banamine IM for pain. Dr. Sergeant ran a full blood panel and prescribed thyroid powder for a slightly low-functioning thyroid. Laser and electrical stimulation therapy was applied as before, but produced little decrease in pain or pulses.

After three days with no relief and symptoms worsening, ice therapy was introduced. Touché's fore feet were kept in ice water for 20-minutes at a time, followed by 30-minutes out of the ice water, for up to eight hours per day. Ice water therapy was able to provide some pain relief. Laser and electrical stimulation therapy were also administered. Pulses would diminish or decrease each day by evening, but would reoccur just as strongly the following day. The mare became very depressed.

Due to the thrombosed right jugular vein and the increased swelling of the head and face, Bute and Banamine IM were reduced. Ketofen was administered, but did not seem to make Touché any more comfortable. Kim Sergeant, DVM took ultrasound readings of the right jugular vein to assess blood flow and found it to be massively occluded with essentially zero blood flow. Dr Sergeant also took radiographs of both front feet and fortunately there was zero rotation in either foot. Due to Touché's substantial pain and increased depression, both the Bute and the Banamine IM were increased. However, in addition to the the right-sided swelling of Touché's head and face, the left side of the mare's head now also began to swell.

At this point, nothing seemed able to halt Touché's rapidly failing health and depression. We felt helpless to stop her continuing downslide. Touché became totally reluctant to move out of her ice water. While on a break out of the ice water, she herself would replace her feet in the ice water. Her appetite began to decrease. At this point euthanasia was seriously considered.

Response To Nitro PRO

On April 26, 2000 we decided to try a new nutritional supplement called Nitro PRO. Nitro PRO is a specially formulated combination of nutrients designed to improve blood flow by promoting the body's production of the vasodilating substance, nitric oxide. Nitro PRO is an all-natural product that contains no herbs, hormones, stimulants, or drugs.

30cc of Nitro PRO powder together with 1-ounce of water mixed to the consistency of slurry in a 60cc syringe, was administered orally on the evening of April 26, 2000 on an empty stomach. All feed was held for approximately 60 minutes post-dosage. Touché at this stage was barely able to move from her hay to her water.

At 6:00 a.m. on April 27, 2000, 12-hours after receiving the first serving of Nitro PRO, Touché was found standing in her stall, her hind legs relaxed, and comfortably bearing her normal weight on her front legs. She walked up to her hay and walked around the stall almost normally. Her feet were no longer warm and pulses were absent in both fore legs. A second serving was administered at that time on an empty stomach. No other treatment was given that day or the next. Pulses were checked around the clock with zero pulsing detected.

Nitro PRO continued to be administered twice daily at 12-hour intervals on an empty stomach as possible. As of today May 5, 2000, Touché has not had any Bute, Banamine IM, Ketofen or any other painkiller since April 25, 2000.

Touché continues to wear Ric Redden Ultimate Shoes taped to her feet. On April 29, 2000 she was active enough to knock off one of the shoes, as a result she had mild pulses on that foot. The Nitro PRO was administered and laser therapy was applied to the acupuncture points around the coronary band and simple ice packs were placed on each foot while the other was being treated with laser therapy. Immediately following laser treatment, all pulsing stopped and was not detected again for two more days.

Upon the return of pulsing, laser treatment was applied in mid-afternoon, following which pulsing was reduced, but not completely eliminated. Nitro PRO was administered that evening and within 15 to 20 minutes, pulsing was undetectable.

Due to Touches' fiery disposition she is not a quiet patient when she is feeling well. While still confined to her bedded stall she is a weaver and pacer and has been bucking in place. Her activities have caused her to tear off her Ric Redden Ultimate shoes numerous times, sometimes with mild pulses returning. However, with the administration of Nitro PRO and simple laser therapy, 20-minutes after receiving Nitro PRO, pulsing has diminished completely. At times it has seemed as if she is in less discomfort than she continued to display between her first and second attack of laminitis.

Prior to using Nitro PRO I was beginning to feel like we were losing the battle. Therapies that had worked so well during my mare's previous attack of laminitis were not effective enough. This time Touché was in such great pain and so depressed, I began to feel nothing but euthanasia would stop her suffering.

We were graciously offered the product Nitro PRO and Touché's response was nothing short of miraculous. Within 12 hours of first receiving Nitro PRO Touché was pulsing-free and found walking comfortably around her stall.

In the last 30 days Touché has not been given any medications or supplements other than the Nitro PRO. She is now bucking in her stall eager to get on with her life.

Dana Meir
San Diego Equine Therapy Center

The photo of Touché taken after treatment with Nitro PRO. A "before" picture was not taken since euthanasia was seriously being considered prior to administering Nitro PRO. Touché was started on Nitro PRO on April 26, 2000. This photograph was taken in August 2000.

Case Study of a Filly With Gastric Ulcers Receiving GastroPLUS PRO

"Whiz"

American Quarter Horse filly
Foaled: February 4, 2000

[Click here to see before and after photos of Whiz.](#)
[Click here to see Whiz's before and after endoscopy images.](#)

GastroPLUS PRO

History:

This weanling filly was purchased by her present owner as a rescue case. The owner felt that with good food and care, this filly would be able to reach her full potential. A monetary deposit was put on the filly approximately two months after birth, with a contract stating that the filly would be properly cared for and delivered after weaning, both healthy and sound. The buyer required this guarantee due to the horrendous condition of most of the other horses owned by the seller. Whiz did appear to be of sound health at the time the purchase agreement was signed.

Shortly after, this filly began to show numerous symptoms of ill thrift and health. In addition to her poor haircoat, and pot-belly, she developed a large swelling under her jaw. This swelling grew and with hot packs applied by the purchaser, it burst yellow/green muco-purulent discharge.

It was concluded through the purchaser's veterinarian that Whiz was suffering from strangles. The filly

became depressed and weak, and her condition worsened. The seller agreed to de-worm the filly with the Ivermectin the buyer had purchased.

The filly Whiz was delivered to the new owner on approximately June 1, 2000. Whiz was found to be listless, extremely underweight, anorexic, had a very poor haircoat, and a bloated belly. All 4 legs were swollen and warm to the touch, especially around the joints. Her left hind leg had suffered a traumatic injury below the hock causing a "curb". The new owner consulted two different veterinarians and tried to restore the filly back to good health with good food and tender loving care.

Unfortunately the filly's worsening condition necessitated transporting her to San Diego Equine Therapy on June 9, 2000 for continuous care. Veterinarian Kim Sergent arrived shortly after the filly and diagnosed severe pneumonia, "curb" in the left hind leg, and ephysitis due to malnutrition. A blood panel was run to see how the filly was doing systematically. The filly's temperature was 102 F. Bute was prescribed for fever and inflammation, and antibiotics were to be started as soon as the blood work results were received.

Whiz's condition worsened. She became even more depressed and anorexic. The filly would nibble on hay only, but refused all grain, supplements, and feeds of any kind. On June 11, 2000 she was started on the antibiotic Naxcel, 15cc IM BID, 2cc Banamine IV, to 1.5cc Banamine IV BID as needed for fever, 10 Zantac (Ranitidine), 2 to 3 times per day, plus yogurt. She was also de-wormed with half dose of Ivermectin, to be repeated in 7 days. Laser and ultrasound therapy were used to treat the curb on the left hind leg. The laser was also applied to all the hot and inflamed fetlock and pastern joints, with poultices and bandages applied thereafter. This was repeated daily.

The antibiotic therapy with Naxcel was continued through June 26, 2000. Blood panels were re-run every 5 to 7 days as needed. On June 27, 2000 the antibiotics were changed to Rifampin and Erthromycin. The Ranitidine (Zantac 75) and Banamine were continued.

While Whiz looked a bit brighter and ate a little better on the new medications, the improvement only lasted a few days. By July 1, 2000 she was worsening. Her fevers did finally come down to nearly normal, but she had become depressed even more than usual.

On July 3, 2000 Whiz was transported to Helen Woodward Animal Center for Dr. Lucy Edens, a neonatal specialist to evaluate and treat. The filly was hospitalized for 3 days and numerous tests were run to help determine Whiz's problems. Transtracheal aspiration, thoracic radiographs, numerous blood tests, and a gastroscopy were performed.

The diagnosis was severe gastric ulceration of the squamous mucosa along the margo plicatus with significant hemorrhage occurring as a result of the ulcers. Whiz was also diagnosed with broncho-interstitial pneumonia, allergic airway disease, encysted small strongyles or other endoparasitism, and immune-mediated polyarthritis.

Her treatment regime continued the same antibiotics, Rifampin and Erythromycin. The rantidine was continued with the dosage slightly increased to 12 instead of 10 tablets 3 times per day. Gastrogard[®] was recommended. The owner wanted to try the another product for treating gastric ulcers called GastroPLUS PRO.

On July 6, 2000 Whiz began receiving GastroPLUS PRO at 15cc of powder mixed in water given twice daily on an empty stomach. Her feed was withheld for 1-hour prior and 1-hour after each dose. The filly's antibiotic therapy continued as prescribed with 3,750 mgs of erythromycin orally 3 times per day and Rifampin 200 mgs orally twice per day. In the hospital, Whiz was de-wormed with Fenbendazole 1-time daily for 3 days. She was continued on the Ranitidine as she had been since June 11, 2000, with the increase from 10 to 12 tablets, 3-times per day. Whiz also continued her daily dosage of Strongid-C, as she had since June 11, 2000.

On July 7, 2000, having been on GastroPLUS PRO for just one day, Whiz's swollen joints and legs were

down to almost completely normal. By July 8, 2000 her appetite had increased from barely eating to finishing most of what she was offered. On July 9, 2000 she cleaned up all of her feed and the next day tried to escape from her stall. She quickly changed from a sad, sick invalid, to a healthy, energetic beautiful filly.

Her antibiotic therapy continued with Rifampin and Erythromycin until July 9, 2000 when her blood panel came back worse than ever, with her WBC count at 18,000 and her fibrinogens up as well. Her previous WBC counts had been 14,000 to 16,000. However, Whiz looked better than ever.

Whiz's antibiotics were changed to SMZs, 10 BID. A belly tap was recommended, but because of her excellent attitude and appearance, the owners decided to hold off on this procedure unless she took another turn for the worse. By July 20, 2000 she was turned out to play for the first time. On July 27, 2000 the blood work came back with her WBC count down to 14,000.

Whiz's attitude and appetite were still excellent. She was very bright, active, and eating "everything in sight". Her dry poor haircoat had changed to very soft and had a brilliant glossy sheen to it. On August 4, 2000, her WBC count was down to high normal of 12,000. Her SMZs and Ranitidine were discontinued. Her owner felt the expense of the Ranitidine was not justified due to the fact that Whiz had been on it since she had begun treatment on June 11, 2000, and had still been diagnosed with hemorrhagic ulcers on July 5, 2000.

Whiz continued on the GastroPLUS PRO at 15cc of powder mixed with water and given orally BID. The cost for Whiz's treatment with GastroPLUS PRO was approximately \$2.35 per serving, \$4.70 per day. This was calculated based on a container of GastroPLUS PRO retailing for \$147.00 each. Whiz was administered 3cc of GastroPLUS PRO powder per 100 pounds of body weight.

On August 30, 2000, Dr. Lucy Edens performed a follow-up gastroscopy examination of Whiz. Repeat gastroscopy revealed almost complete resolution of the gastric lesions, with only a few small erosions remaining. Whiz had begun receiving GastroPLUS PRO on July 6, 2000.

Dana Meier

San Diego Equine Therapy

Don't allow your horse to suffer needlessly. [Click here to order GastroPLUS PRO.](#)

Letter From Veterinarian:

Lucy M. Edens, DVM, MS, Diplomate ACVM
Equine Internal Medicine
P.O. Box 232827
Encinitas, CA 92023
(760) 634-1646

Dear Company,

This letter is in reference to the horse Whiz. At the time of initial examination on July 5, 2000 the foal was suffering from chronic respiratory disease, immune-mediated polyarthritis, gastric ulceration and failure to thrive which was presumed to be secondary to severe endoparasitism. Gastroscopy on July 5th revealed severe ulceration of the squamous mucosa along the margo plicatus with significant hemorrhage occurring as a result of the ulcers. Treatment encompassed lavacidal doses of fenbendazole, erythromycin and rifampin, rantidine and GastroPLUS PRO. Reevaluation on August 30, 2000 revealed considerable improvement in Whiz's condition. She had gained weight and shed out completely. All clinical signs of respiratory disease and polyarthritis were resolved. Repeat gastroscopy revealed almost complete resolution of the gastric lesions, with only a few small erosions remaining. It was recommended to continue the GastroPLUS PRO for an additional week to help ensure complete resolution of the gastric erosions.

Thank you for your willingness to provide the GastroPLUS PRO and to pay for the follow-up evaluation of Whiz. That was more than generous on your part. Because of the many complex factors involved in this

case it is difficult to know if any one specific therapy resulted in her improvement. Most likely it was a combination of all the treatments she received in addition to the wonderful care that Linda and Dana Meier provided to her. Do not hesitate to contact me if I can be of additional help.

Sincerely,

Lucy M. Edens, DVM, MS, Diplomate ACVIM

[Click here to see before and after photos of Whiz.](#)

[Click here to see Whiz's before and after endoscopy images.](#)

Case Study - Gastric Ulcers Case Study 2

3 young Arabian horses:

- Psyches Minx 1999 filly
- Brilliant Psyche 1998 stallion
- The Silken Swan 1996 mare

GastroPLUS PRO

Veterinarian diagnosis: 3 horses with probable gastric ulcers, due to circumstances and symptoms, and blood work.

Brief history: March 2002. 3 young Arabian horses. Psyches Minx 1999 filly, Brilliant Psyche 1998 stallion, and The Silken Swan 1996 mare. All 3 had the same owner since birth, and were part of a group of horses boarded with a caretaker while the owner moved to another state, and set up a new barn. Unfortunately, after substantial board money was paid in advance and the owner moved to set up a new facility, these 3 horses along with 11 others were starved. Upon arrival from a commercial hauler to the new facility, all but 1 of the 14 total horses had lost between 200 and 300 lbs. One 23 y/o mare collapsed while being unloaded. Veterinarians were called, and emergency treatment was begun on all who needed it. Careful feeding programs were initiated for each horse individually, to help them to recover. All horses were started on electrolytes, iron and vitamin supplements, and probiotics. The 3 horses listed above, did not bounce back as was hoped for. Blood work was ran, and showed severe anemia, muscle wasting, due to starvation, and The Silken Swan showed kidney and liver failure. All 3 were reluctant to eat, especially sweet feeds of any kind. The only feed accepted was grass hay, all other was rejected. They were extremely listless and weak. Scoping for the presence of gastric ulcers was recommended, but the nearest facility was several hundred miles away, causing even more stress for these horses, and finances were also a consideration.

These 3 horses were started on GastroPLUS PRO. All were dosed at 3cc per hundred lbs. 2x daily, for 14 days, and 1x daily for another 14 days. The colt began eating within 48 hours on the GastroPLUS PRO, and the other 2 within 72 hours, were eating normally again. Energy resumed, and all 3 horses began to quickly pick up weight. By the end of the 30 days, all looked and acted normal again. Their coats were completely shed out, and they had brilliant shines. The stallion, who had required double feeding all his life to maintain good weight, has been able to maintain excellent weight and condition on a regular amount of feed for his size since being on the GastroPLUS PRO. His temperament also changed. He is a much calmer, happier stallion to have around, and has no nasty habits. He is now 5 years old. None of these horses has had any reoccurrences.

After these horses had responded so well to treatment with GastroPLUS PRO, another, an 18 y/o gelding was also put on the product. He had been recovering and picking up weight, but not as quickly as the other horses had. He was a little listless, and just not himself. He was put on GastroPLUS PRO 30cc powder 2x daily for 7 days, then 1x daily for another 3 weeks. He quickly picked up weight, and strength, and recovered fully.

Case Study - Navicular Syndrome, ring bone, side bone

5 different horses:

- (2) 7 y/o Hannoverian geldings
- (1) 23 y/o AQHA gelding
- (1) 17 y/o AQHA gelding
- (1) 20+ large pony mare.

Nitro PRO

Veterinarian diagnosis: Navicular syndrome, ring bone, side bone. 5 different horses, all diagnosed with radiographs.

Brief history: All 5 of these horses were diagnosed at San Diego Equine Sports Therapy by (2) different veterinarians over a period of approximately 3 months. All 5 had symptoms of navicular syndrome, and subsequent ringbone and sidebone. All were radiographed to confirm diagnosis. All were grade 2 to 3 lame. All had been shod with special shoes and pads. And all had been treated with phenylbutazone. All had deteriorated to the point of being non-ridable. All had received Adequan injections. The 2 Hannoverians and 23 y/o AQHA had been treated unsuccessfully with Isoxsuprine. These 3 also had been on the joint supplement "Next Level". The 23 y/o was treated with laser and ultrasound therapy with about 75% success in making him more comfortable, but required 2 weekly treatments to maintain comfort. (1) of the 7 y/o's also received therapeutic ultrasound, and laser therapy with about 50% success.

All 5 horses were put on Nitro PRO, at regular doses of 3cc powder per 100 lbs. body weight. This was the dosage at two times per day for 7 days, then one time per day thereafter. It was recommended to the owners that all the horses be taken off all other medications while on the Nitro PRO, but since this was not an official case study, the owners were not required to comply. (2) of the horses, (1) 7 y/o and the 23 y/o remained on high doses of bute (2 gms. 2x per day) Plus the 23 y/o was on banamine every time he was turned out. These 2 horses had a minimal response to the Nitro PRO. (3) remaining horses did not receive any bute or banamine or isoxsuprine while on the Nitro PRO. **These 3 horses showed a marked improvement while on the Nitro PRO.** Approximately 80% better, than how they felt on the bute, banamine, and the (1) who had also been on the isoxsuprine. **All 3 of these horses became ridable again, after 1 bottle per horse of Nitro PRO. All 3 went off all other medications.**

The 2 horses that remained on bute and banamine while on the Nitro PRO had minimal improvement. Probably/possibly due to Bute, banamine and other anti-inflammatories are Nitric Oxide inhibitors, thus the product was not allowed to work. The 7 y/o was given away to become a pasture ornament. The 23 y/o underwent a neurectomy, with about 50% success, and was retired to pasture. Neither of these horses became ridable again.

The 3 who did have excellent success, had all been taken off all other medications, prior to and during treatment w/ the Nitro PRO. None of these horses remained on the product after the 1st bottle. **The 7 y/o Hannoverian gelding was considered totally unridable.** He had previously been a dressage horse and a hunter. He had numerous problems diagnosed, besides the navicular, ring bone, and sidebone. He had numerous neck, and back problems, and DJD in both hocks. His owner spared no expense in diagnostics

and treatments. He was referred to 2 different surgical facilities for diagnostics, and treated at San Diego Equine Sports Therapy, with the treating veterinarian overseeing his care and treatments. He received therapeutic ultrasound, laser, electrical stim, and massage. Along with chiropractic and Acupuncture from the veterinarians. **The Nitro PRO was introduced after approximately 1 month of all the other treatments. He had improved, but only to the point of light hacking, and was considered unable to compete again. The administration of the Nitro PRO appeared to be the major turning point in this valuable horse's future. He responded even better to all of his treatments, and was sent home 3 weeks later. This horse went on shortly after to become #2 in the county as an open hunter on the "A" show circuit, in an extremely competitive circuit. To date, he has had only a few minor setbacks that were easily treated with therapy.**

Case Study - Rattlesnake Bite

Injury PRO has been used with impressive results in the treatment of rattlesnake bite. A 23 year old mare named Lindsey was bitten by a rattlesnake on her right hind leg after having been bitten on the same leg a year before.

[Click here to see before and after pictures.](#)

Horse's name: Lindsey
23 Year old mare
Running quarter horse
Height 15.1 H.H.
Weight 800 lbs.
Primary use: Pleasure and trail riding
Consulting veterinarian: Kim Sergent, DVM

Injury PRO

In August of 2000, Lindsey a 23 year old mare, was bitten by a rattlesnake on her right hind leg. Coincidentally and unfortunately, this mare was bitten one year before on the same leg. Her attending veterinarian was called immediately, but due to the severity of the situation, he did not feel the mare would survive this second encounter.

Lindsey was treated minimally with the expectation that she would die. The mare did not die as expected, but her leg became grossly swollen and began to slough all of the skin from her coronary band to above her hock. Puss oozed from pockets as high as her udder and stifle. A massive infection had set in with accompanying necrosis, and she was unable to bear weight on her leg. Her opposite supporting limb also swelled to at least four times its normal size and blood trickled from her nostrils almost constantly.

The attending veterinarian was called out several times and he felt the infection had settled in the opposite leg as well, and that her body was shutting down. Surprisingly, the mare's temperature remained normal.

The mare lost over 100 lbs. in nine days. On day-nine the owners called San Diego Equine Therapy for help. The mare was transferred to a deeply bedded stall and a companion mare was brought in for comfort. Lindsey's supporting leg was wrapped and the treatment regime for cleaning the bad leg was changed. These changes in treatment improved the mare's attitude.

Photos were taken from day-nine through day-sixteen. The mare was started on the product Injury PRO, hoping it would help with the body's own healing process and oxygenation. An appointment was made for the following day, (day-nine was a Sunday), for a different consulting veterinarian to come and attempt to help. The owners were grateful for the little hope that there was, but realized their mare would probably be put to sleep when this veterinarian arrived the next day.

Injury PRO was given every eight hours and the mare had been receiving the product for 24 hours when

the new veterinarian arrived. The mare's nose bleed had almost completely stopped. The bleeding began again for a few moments when Lindsey became upset because the companion mare moved out of sight. The bleeding stopped when Lindsey calmed down.

The mare's eyes were brighter and her supporting good legs' swelling was down about 50% in less than 24 hours. Her bad leg was less swollen and she was able to bear some weight on it. Her temperature was still normal when the consulting veterinarian, Dr. Kim Sergent, arrived. The doctor felt the mare had a grave prognosis, but was willing to try aggressive treatment for the next day and see how well the mare did.

Dr. Sergent changed and added to the cleaning and bandaging techniques, prescribed Metronidazole and instructed the owners to continue administering the Injury PRO. Dr. Sergent also ran a complete blood panel on the mare to see how she was doing systemically. She strongly felt that the mare would slough off her hoof eventually.

The owners wanted to try everything possible before giving up on the mare. Lindsey did not lose the hoof and over the next seven days, the mare steadily improved. Her owners were diligent in her care, scrubbing, cleaning and debriding the leg themselves.

The mare's medications and the Injury PRO were given exactly on schedule and her stall was kept immaculate with deep bedding. Lindsey was walking without even a limp, the wound was filling in with granulation tissue and hair had begun growing back on the upper leg. The oozing pus had stopped and the smell was almost completely gone. Her good leg returned almost to its normal size. The daily photos show the the body's own healing process to be quite dramatic.

On the eighth day of using Injury PRO, which was day-seven of treatment on antibiotics, the consulting veterinarian further debrided the leg. Dr. Sergent also recommended skin grafts in the future and although Lindsey was not quite out of the woods, the mare appeared to be on her way to recovery.

The unfortunate part of this story is that the owners "ran out of steam." They had worked so hard, but the ordeal took a toll on the entire family. They backed off on their treatment regimes, the amounts of Injury PRO given were decreased, and the cleaning and changing of bandages became less frequent. The mare became depressed and was unable to walk without obvious pain. The owners felt they might not have what it would take emotionally and financially to see Lindsey through this entire ordeal. The owners did not want the mare to be in any more pain and decided to have the mare put to sleep.

Dana Meier
San Diego Equine Therapy

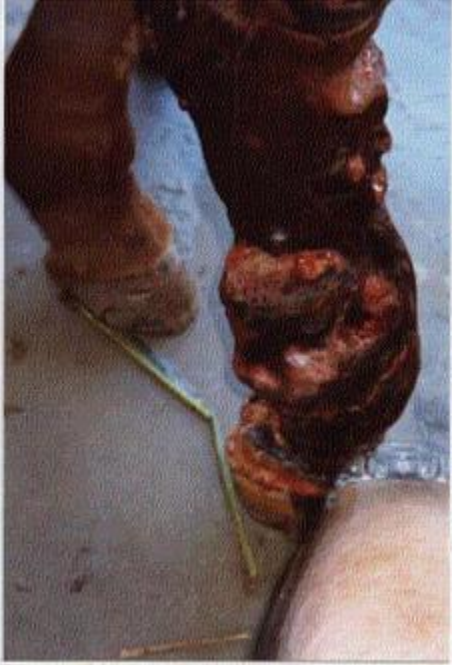"Lindsey's progress over the initial seven days after starting with the Injury PRO and more aggressive medical therapy was truly amazing. Specifically, the reduction in swelling and infection, improvement in comfortability and the speed of healing. All of these things were potentiated by the addition of Injury PRO to the mare's treatment regime. With continued appropriate therapy and Injury PRO, this mare's chances for complete recovery escalated from grave to good in a week's time.

Unfortunately, as with many intensive care equine cases, emotional burnout and financial burdens create the necessity for euthanasia, as in this case."

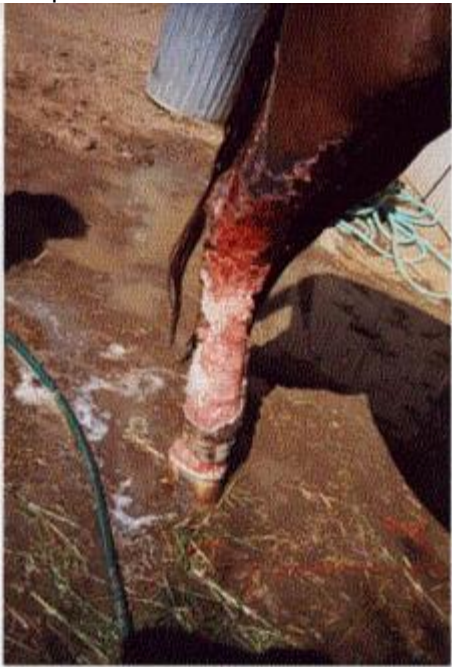Kim Sergent, DVM

Promoting Wound Healing with Injury PRO Before & After Pictures

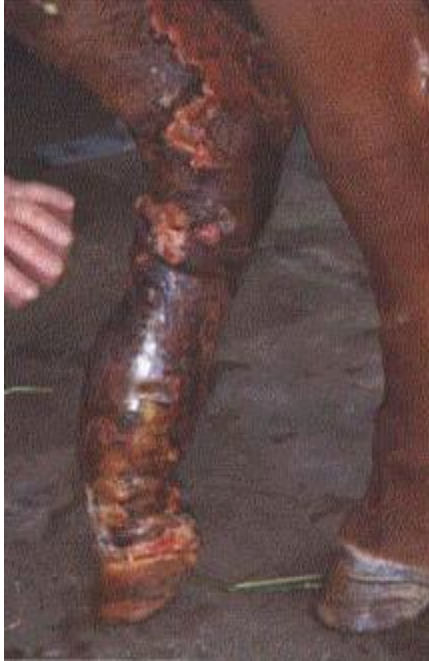The first photo was taken 9 days after a mare, Lindsey, was bitten by a rattlesnake.




This photo was taken on the seventh day Lindsey was receiving Injury PRO.



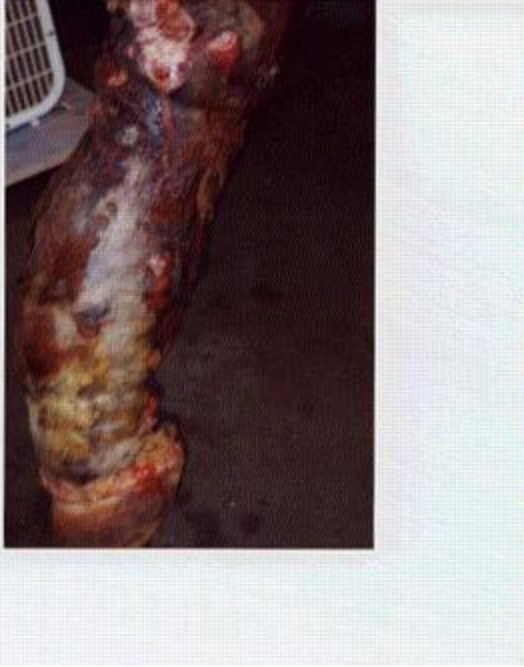Before... (August 13, 2000).



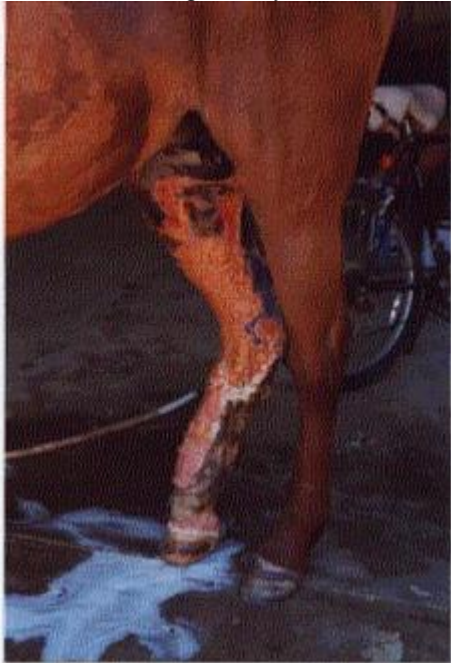The following photograph was taken on August 19, 2000, the seventh day Lindsey was receiving Injury PRO.



Before... (August 13, 2000).




After... on the eighth day the mare was receiving Injury PRO, August 20, 2000.



Testimonial – Poor Keeper, gravel

“Sinatra”
20 y/o QH gelding



16.1 HH

1000 lbs. approximately

Same owner since 1992

Primary use: as a trail horse and lesson horse (was shown Dressage, H/J, & Eventing when younger)

Nitro PRO, Injury PRO & GastroPLUS PRO

Summer 2006 Sinatra was leased out as a pleasure trail horse. He was ridden in high desert areas 3-4 times a week for 2-4 hours each ride. Although he was in shape when he was returned he was down in weight, down in the back, had a hatchet neck and large wind puffs around both hind pasterns. The before picture was taken after a swim in the lake.

When he was returned, he was kept on the same feed and not ridden to allow the legs to heal. After 3 weeks he had not gained any weight and the wind puffs were still extremely large. Around that time I heard about the Nitric Oxide products.

Sinatra was given a double dose (60cc) of Nitro PRO in the morning and 60cc's of Injury PRO in the evening. Within one week he gained weight, became more animated and the wind puffs had decreased to a very slight swelling. Dosing of both products continued for the next two weeks at the suggested 30cc amount. The after picture was taken on the 3rd week. He had plumped out to his original self, had a nice bloom on his coat (although sun bleached), and the wind puffs were barely noticeable.

On the 4th week we gave him Injury PRO in the morning and GastroPLUS PRO in the evening. Within three days of this protocol, his coat became jet black, and his lovable personality returned.

Post Note:

One month later, a gravel abscessed above the coronet band, on the left front leg, over the inside bulb. Sinatra was lame and pointed when he stood. He barely nibbled at his feed and left most of it. The abscess was nasty...an explosion of granular flesh, puss and blood, an inch long. We called the farrier who could not come out until the next day. We soaked the hoof in Epsom salts twice that day and started him on a double dose of Nitro PRO in the am and a double dose of Injury PRO in the evening. When the farrier arrived the following day we were almost embarrassed because it looked so good. He said it looked days old and there was really nothing that he needed to do. We continued with the Nitric Oxide products for a month.

Three weeks after the gravel abscessed we had Sinatra at the vets as a companion horse for another horse we took in. We had the vet look at the hoof to see if there was anything we should be doing for it. He asked us how old it was, "Three Weeks", he was amazed and said it looked like it had 2 months of healthy growth on it.

Sinatra was not lame one day since we started him on the products and we could not be more pleased with the results!

Case Study – Face Injury



"Castaway Robin"



14 y/o APHA Mare
15.2 HH
1000 lbs. approximately
Primary use: as a trail horse and brood mare
Pictures: When It Happened - 3 Days Later

Nitro PRO, Injury PRO & GastroPLUS PRO

"Robin" was found in her stall with what looked like a hoof print around her eye that resulted in an indentation below and in front of her eye. She had blood dripping out of her nose and the eye was weeping.

She was taken to Desert Pines Equine Center for x-rays. During sedation, the tear duct was irrigated (no blockage), and the eye was thoroughly examined. Because of the location, it was hard to determine if there was a break when looking at the x-rays. A quarter inch ulcer was detected on the eye.

The vet prescribed the following:

Administer triple antibiotic ophthalmic ointment to the left eye every 2-4 hours.

Administer 1 gram of Bute every 12 hours for 4-5 days, and then decrease to 1 gram every 24 hours for another 3-4 days. For the inflammation and swelling in the head.

Administer 15 tablets of trimethoprim/sulfa every 12 hours for the next 8 days.

Knowing the power of the Nitric Oxide products we substituted Injury PRO for the Bute and there was not ANY swelling, we were amazed! We also decreased the antibiotics by half because the Nitric Oxide increases the strength of anything else you give the horse. After 3 days, the weeping stopped, she showed no indications of pain, and ate everything she could find. Aside from a little dent in her head her sight, appetite and personality back to normal.